

Treating Burnt Wildlife

By Dr Anne Fowler

BSc(Vet)(Hons), BVSc, MACVSc (Avian Health)

Colleen Wood

Wildlife Shelter, Rawson, VIC

Introduction

In January 2006, wildfires began in four parts of Victoria and destroyed bushland over the following month. The challenge was to provide good quality information to carers in isolated areas when most of these carers had never previously cared for burned victims.

Dealing with burnt wildlife involves interaction with a variety of government and community-based agencies, whose priorities are to save human life and property. The goal with burnt animals should be accurately assess, promptly treat those able to be rehabilitated and provide compassionate euthanasia to those suffering from extensive burns. Animals may present from these large-scale fires, or from local small-scale back-burning operations that occur during the cooler months of the year.

Assessment of Burns

The first thing to understand is the role of skin – from this we can appreciate what happens when it is damaged or lost. Skin is the largest organ in the body. It is responsible for keeping fluid in the body. It acts as a barrier to invasion by external organisms – such as bacteria and fungi. It provides a surface that allows us to feel our environment, without being damaged by it. The body is continually replacing the skin – it takes 12 weeks to grow from the deepest level to being shed as dead cells.

Without skin, fluid and electrolytes are lost from the body. The body requires more energy to replace the skin, so metabolic requirements increase. Susceptibility to infection occurs. Movement becomes painful and further loss of blood and tissues is likely as the underlying tissues are unable to cope with trauma.

There are a few things to consider when assessing burns:

- Depth of the burn
- Extent of the burn
- Location of the burn

Depth of the burn

This was described as first, second and third degree burns. However, the terminology below is descriptive and able to be understood by people without training in burns.

1. **Superficial burns:** involves the outermost layer of the skin. This is very painful. The skin is red, but not blistered. This was a first degree burn. The best example is of this burn is when you burn yourself on a hotplate. It is uncommon that this burn is seen in wildlife. Bird skin does not blister as prominently as mammalian skin as it lacks collagen.

2. **Partial thickness burns:** involve the deeper levels of the skin. It is painful and was known as second degree burns. There are two levels of partial thickness burns:

Superficial partial thickness: The skin begins to blister but will heal within 2 weeks without scarring.

Deep partial thickness: The skin is blotchy with red or white areas. Blisters may be present. Nerves have been destroyed as so it is not painful. This burn will take 2 – 4 weeks to heal with possible scarring.

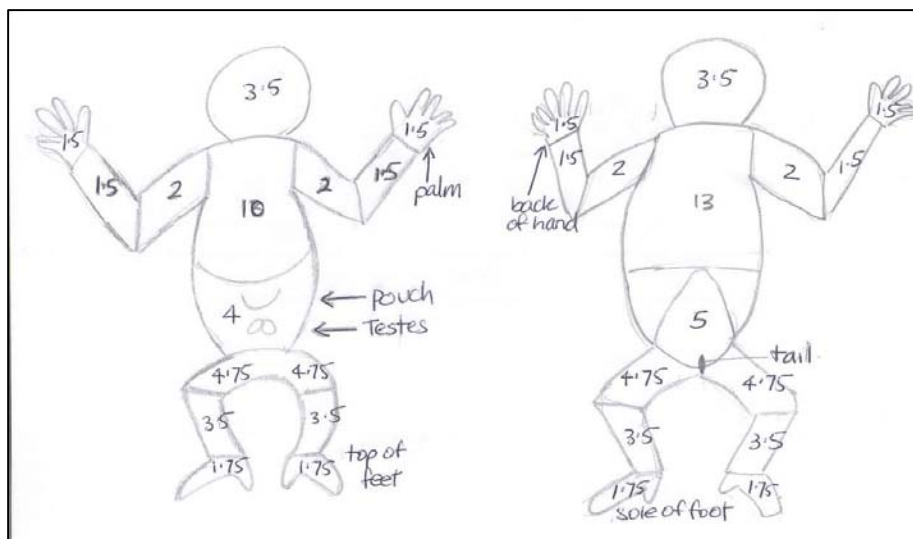
3. **Full thickness burn:** destroys the full depth of skin, including tissues below. This will take at least 2 – 4 weeks to heal – dependent on the size of the burn. Escharotomy which involves cutting away the dead skin and suturing fresh edges together may be required for areas with full thickness burns.

Extent of the Burns

The amount of skin that has been burned needs to be considered. As carers and vets, we are unable to induce month-long comas, do extensive skin grafting and repetitive surgeries on these animals. The welfare of the animal must remain our prime concern. It is not fair for the animal to suffer with no chance for rehabilitation. So an assessment of the severity of the burns is needed.

- Burns to less than 15% of the body have a reasonable prognosis
- Burns to 15 – 50 % of the body have a poor prognosis
- Burns to over 50% of the body have no prognosis and prompt euthanasia is required.

We describe the area burned using the sketches below to calculate the area burned. This is taken from the Lund and Browder Charts for humans and is based on a koala body.



Areas are based on surface areas for adults. Please excuse the sketches – I failed Art! The tail on possums could be included in the buttocks area. However, it would rate higher for an animal such as a macropod in terms of surface area.

Location of the Burns

For wildlife, whose release is dependent on a functional body, some locations of burns may impact on rehabilitation.

- Damage near joints where scar tissue restricts the movement of limbs or digits has a great effect on our tree-dwelling marsupials. This is also pertinent around face structures such as eyelids and mouth.
- Nail bed damage is significant. Nails are used to climb trees to eat and escape predation, to groom, to fight, to care for young. An animal may cope with one nail lost on a hand, but more than one nail lost may affect its survival.
- Burns may be hidden by feathers and the true extent of the burn is not appreciated.

First Aid... First

Often in the drama surrounding the fire and the obviousness of the burns, the patient is forgotten. We also need to remember that this is one occasion where we all need to work as a team – the person collecting browse or doing the washing is as integral as the person changing the bandages.

The entire animal should be assessed and treated.

The following things are important in the procedure of treating burns

- **Examine the Animal and Collect Vital Signs**

What is the mental status of the animal? Is it bright, alert, dull, or quiet?

What is its breathing like? Fast, harsh, gurgly, or moist? We are looking for animals with smoke inhalation or burns.

What is its heart rate? A shocky animal will have a fast heart rate.

Pinch the skin. Does it tent? This indicates at least 10% dehydration.

What is the gum colour? Is it pink or white? What is the refill time when you press on the gums? It should be 1 second; longer indicates shock.

Is a joey present? If it is dead, remove to prevent infection of the pouch. If the joey is alive, and the mother lactating, then an individual assessment is made as to whether to keep the joey and mother together – based on severity of burns.

When possible, weigh the animal – to gauge future losses or gains.

- **Treat for shock.**

Keep the animal warm, dark and quiet. The temperature should be between 24 – 30°C

Minimize human traffic and noise. Keep pets and children away.

The environment that houses the animals should be kept clean – and fly strike prevented.

- **Treat dehydration.**

These animals have been stuck in a tree in hot air leading up to and through the fire front. Ambient humidity of air may only be 10% instead of 50%. Leaves which are food and water may have shriveled and died. Rehydration is essential. Offer fresh water – and yes, every animal – including koalas, will drink water if it wants it. Leave fresh water available at all times – but remember that the animal may be too disorientated or sore to move – so continue to offer water several times a day.

Treat for a minimum of 10% dehydration – and ideally 20% dehydration – for at least 3 days. Some animals will require a longer time to rehydrate. Aggressive rehydration prevents later problems with kidney damage.

Fluids can also be given subcutaneously or intravenously. Fluid will be absorbed from the subcutaneous space over several hours – making this suitable for more alert animals where you wish to minimize handling.

- **Treating the burn**

In the true first aid setting at the fire front, the initial treatment of a burn is to flush it in tepid water for 10 minutes. The goal is to stop the ‘microwave’ effect. The skin traps heat and the subcutaneous fat continues to burn – thus the burn extends. Flushing the burn will also remove some of the debris such as soot and plant material.

When it comes to treating burns, the first thing to do is to get organized. Lay instruments out ready for use, have bandages cut to size and work from a clean side to dirty side.

- It is appropriate to use **disposable gloves** when treating full-thickness burns to prevent the transfer of bacteria from your hands to the burn.
- Trim off singed fur with **scissors or clippers** so that the skin can be examined.
- Bathe burns in tepid 0.9% **saline** for 5 – 10 minutes. The longer time is necessary initially and can be reduced over time. Change the water when it becomes dirty.
- Bathe eyes with saline. Wipe soot away from conjunctiva.
- Moist cotton buds are used to clean the nostrils.
- With sharp scissors, trim away any flaps of dead skin.
- Dry the burns with **cotton gauze** or cotton toweling. Cotton wool balls leave strands of cotton on the wound and should not be used.
- For the first 3 – 5 days while the wounds slough (debride), a **saline wet to dry bandage** is changed daily. Moisten cotton gauze with sterile saline. Then apply dry cotton gauze over the top and then wrap.
- Apply **Silvazene** (Smith & Nephew) to the affected areas liberally. Cover all burnt surfaces – not just front and backs of hands or feet. There is no other cream that is suitable for partial to full thickness burns. The silver promotes healing and the sulphadiazine is antibacterial and antifungal in its action. Application of Silvazene stops when there is a complete covering of skin.
- Apply a layer of **Melonin** (Smith & Nephew) shiny side facing the burn.
- Paraffin can be used but in the early stages may leave its indentations on the granulating wound bed. It is suitable to wrap around burnt tails.
- Wrap the feet in mittens. Mitten bandages leave the opposing thumb bandaged separate to the remaining fingers. In this bandage, animals are able to grab browse. Do not bandage in ‘ball’ bandages taught in human first aid – these are uncomfortable in the longer term, do not allow the animal to feed and do not permit normal walking. Bandage material such as **Coplus, Vetrax** can be used.
- **Acticoat 7** (Smith & Nephew), can be used after the first week for animals that require regular anaesthesia for bandage changes – this dressing stays moist and releases silver over a 7 day period – suitable for birds and possum burns.
- After 5 days, bandage changes can be performed every second day. Do not delay changes longer than two days as Silvazene is only active for 24 hours.

Supplementary feeding

The metabolic requirement of burnt animals is three times their maintenance requirement. There is a high protein requirement to make cells to fight infection and to heal.

All animals should be provided with natural browse. However, supplementary feeding permits the provision of fluids, energy and a source of protein.

Milk is well-suited for this purpose. Koalas are fed 60 – 120 ml of Divetalact/Prosobee/Biolac M200 daily. Whatever milk you are accustomed to use for possums can be offered for lapping. Birds may benefit from being crop fed Handrearing mixes.

Access to fresh water at all times is recommended.

Medications for Burnt Animals

Please remember that many medications are required to be prescribed by your veterinarian for an individual animal by law. It is strongly recommended that you involve your veterinarian in the treatment of burnt wildlife.

- Antibiotics are required for a minimum of 7 days, and usually two weeks while the necrotic tissue is debrided.
Amoxil/Clavulox is suitable for kangaroos and Brushtail possums. It has an excellent spectrum against skin bacteria (such as Staph) likely to invade the wounds.
Baytril, by oral or injectable routes, is suitable for koalas, ringtail possums, reptiles.
- Pain relief is recommended. Metacam, a non-steroidal anti-inflammatory, has been used with success. Ensure that the animal is well-hydrated with use of both antibiotics and antiinflammatories. Pain relief is required until the skin reforms – at this point the nerves are protected. Each case needs to be assessed individually.
- Vitamins are open for debate. Stressed koalas benefit greatly from B group vitamins. However, an animal that has been starving will also benefit. Vitamin A is required in making healthy skin. Ideally the vitamins will be found in the diet offered.
- Sedation is recommended for the first week of bandage changes as the dressing changes are very painful. As healing progresses, the animal may no longer need sedation. Full general anaesthesia may be required to change the dressings of possums and birds. Please keep the welfare of the animal in mind – if the dressings are painful, seek veterinary assistance for sedation or anaesthesia.

Progression of Burns

It can be difficult to know what to expect from a burn. However, we need to understand that all wounds follow the three stages of healing:

- **Inflammatory stage** (day 1 – day 5) where removal of dead tissue & resolution of infection occur.
- **Proliferative phase** (day 5 – day 14) where granulation tissue covers the wound
- **Remodelling phase** (day 7 – day 28) where skin covers the wound.

So in the first week, we see a weepy, infected wound, with lots of discharge (necrotic tissue). Bandage changes are required daily.

By day 7 – 10, the eschar (burnt dead tissue) lifts. It may only be at this point that the severity of the burn becomes apparent. A proportion of animals may require euthanasia at this point

due to extensive damage to underlying structures. Bandage changes can now be done on alternate days.

By day 14 in a well-treated partial thickness burn, granulation should have begun and some areas of the burn may already have intact skin. Nails are often only starting to fall off at this point. The nail bed is very sensitive and needs to be covered in a bandage while it heals – which may easily take a month or so.

If there is any delay in progress of a burn by 14 – 21 days, the burn should be reassessed: is it infected, is it drying out?

Equipment to Treat Burns

0.9% sterile saline

Tissue scissors

Silvazine

Betadine 1% or Chlorhexidine gluconate scrub (not alcohol-based)

Melonin

Paraffin gauze

Cotton gauze, cotton buds, cotton makeup pads

Basin to hold water for cleaning

Bandages: crepe bandages, Vetrax, Coplus

Cotton mittens have been made by some carers.

Rehabilitation

A pre-release assessment by a veterinarian is recommended – this may involve examination of the healing areas, taking blood, identification of the animal if permitted, etc.

The suitability of both the koala and the environment needs to be considered. Fires differ in their severity: a crown fire needs many months of regeneration before it can sustain life; a grass fire or low-level fire may be suitable to return animals to much sooner. However, ringtail possums are dependent on undergrowth so they do not need to go to the ground (where the predators are), and thus burnt areas may not be suitable for this species for some time.

Placing animals in adjacent and unburned areas may affect the resident wildlife there and serious consideration needs to be given to this undertaking.

Returning the animal to its original location and ideally, within its family group would be the goal to aim towards.

If animals are to be translocated, then it is important that they do not carry disease to the new location; eg; Chlamydia and koalas.

Epicornic growth is thought to be less toxic than mature growth and can be used as food – however, overstocking reduces the amount of epicornic growth and may affect how the tree recovers over the longer-term.

Consultation with government agencies responsible for the land is required prior to release. It would be tragic to release an animal only for it to be injured by heavy machinery engaged in rehabilitation of the area present for salvage logging, road building or further back-burning.

Changes to a population of common ringtail possums (*Pseudocheirus peregrinus*) after bushfire

B. G. Russell, Barbara Smith and M. L. Augee

Wildlife Research 30(4) 389 - 396

Abstract

Following bushfires in Sydney in 1994 a population of 20–30 common ringtail possums (*Pseudocheirus peregrinus*) that had been studied for four years was reduced to only one or two animals. In the intervening years population numbers remained at this low level. Four years after the fire, 22 ringtail possums were introduced into the study site and radio-tracked for 30 weeks. Nest usage shifted from predominantly dreys before the fire to an equal amount of time spent in dreys and tree hollows. Proportionally, the mortality due to predation by lace monitors (*Varanus varius*) and diamond pythons (*Morelia spilota spilota*) increased. Within 12 months the population returned to only two animals. We conclude that increased predation by native predators, added to continued predation by foxes and cats, has maintained a level of predation beyond a threshold that would allow the ringtail population to re-establish to previous levels.

References

In writing and refining these notes, I am indebted to a number of people who have helped. Cheyne Flanagan for the use of the excellent burns protocol by Port Macquarie Koala Hospital as a basis to work from. Marilyn Blankley and Gordon Lyall for their tireless work caring for and photographing the burns so that we can all learn from the experiences of Bear, Momma K, Verna and Heidi; Patti Durnin for bringing her nurse expertise forward to make helpful additions to the burns protocol; Helen Cameron and others from Smith and Nephew P/L for directing me to a number of resources on healing burns.

Port Macquarie Koala Hospital Burns Protocol, 2002

www.smith-nephew.com.au/healthcare

www.rch.org.au/burns/clinical/index.cfm?doc_id=2012

Herbivore damage, resource richness & putative defences in juvenile vs adult Eucalyptus leaves. By EA Gras, J READ, CT Mach, GD Sanson, FJ Clissold in *Aust J Botany*, 2005, 53 p 33 – 44.

Changes to a population of common ringtail possums (*Pseudocheirus peregrinus*) after bushfire. By BG Russell, B Smith, ML Augee. *Wildlife Res.* 30 (4) 389- 396

Assessment of the Depth of the Burn

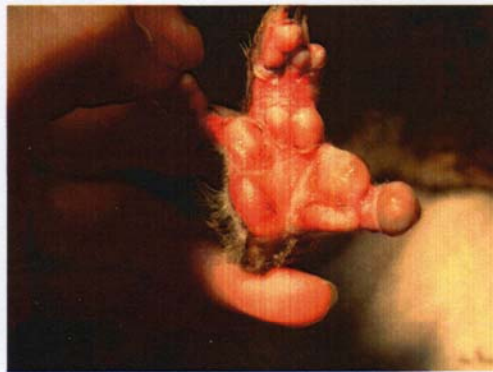
Partial Thickness Burn Superficial

Blisters present. If blisters are broken, red base is seen.



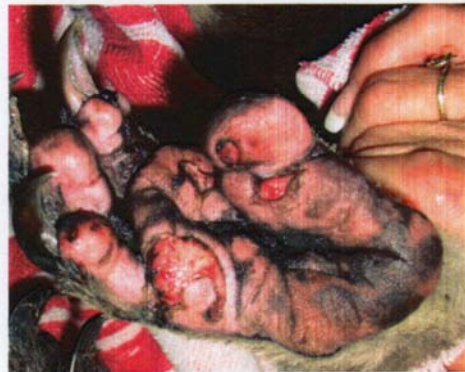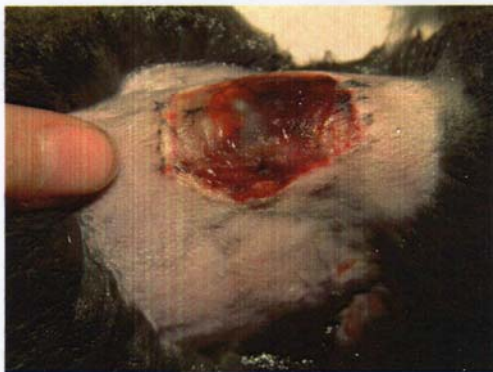Partial thickness Burn – Deep

Appears blotchy – with red and white areas.

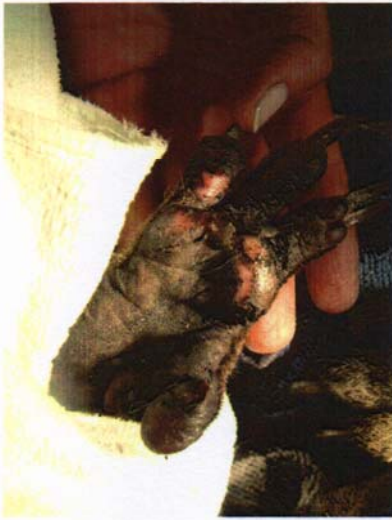

Full thickness Burn

Appears leathery, white or charred. Not painful as nerves are destroyed.

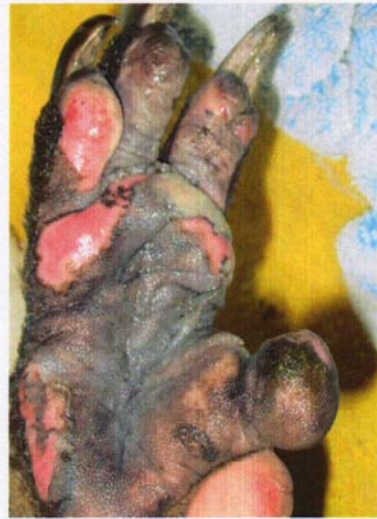

Progression of Burns on Koala Feet over Time



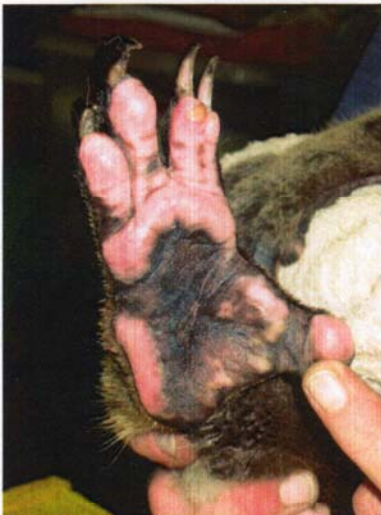Burnt foot on admission. Note the soot obscures the severity of the burns. Blisters and lifting edges of skin are visible.

Photo by Anne Fowler



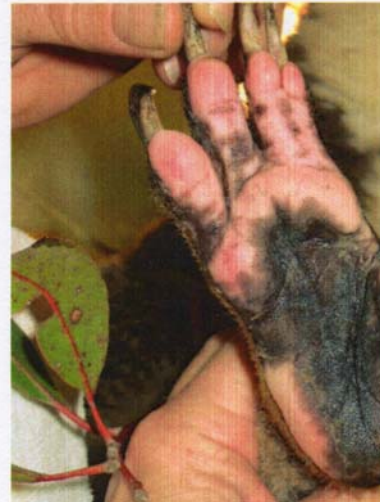Same foot 3 days later. Extent of burn is becoming apparent. More necrotic skin is lifting. This is a deep partial thickness burn. But the toe pads of digit 3 and 4 are deeper burns.

Photo courtesy of Marilyn Blankley



Day 13. Dead skin has been debrided. A new layer of skin is developing. Burn on digit 2 is slower to heal than other areas.

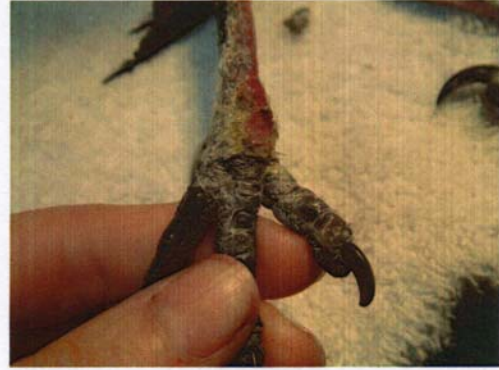Photo courtesy of Marilyn Blankley



Day 26. Pigmentation is returning. Foot no longer requires bandaging. Koala "Bear" is housed outside.

Photo courtesy of Marilyn Blankley

Burns in Different Species



Burnt foot of a Magpie, 3 days after electrocution incident... and one month later – deep partial thickness burn. Loss of scale on leg 2 weeks ago now healing with granulation tissue.



Burnt blue tongue lizard (photo courtesy of Robert Johnson). Deep partial thickness burns around face. Successful release.



Wing membrane of Grey-headed Flying Fox. Central area is black – full thickness burn with eschar. Note the redness around the third finger – partial thickness burn is present. This injury was a consequence of electrocution.